



# Craniofacial and Oral Manifestations of Non-Syndromic Hypodontia: A Review

Khaled Khalaf<sup>1,2</sup> Mohamed El-Kishawi<sup>1</sup>

<sup>1</sup>Department of Preventive and Restorative Dentistry, College of Dental Medicine, University of Sharjah, UAE

<sup>2</sup>Institute of Dentistry, University of Aberdeen, United Kingdom

Eur J Gen Dent 2022;11:17–22.

**Address for correspondence** Khaled Khalaf, PhD, BDS, DAS (Orth.), FDS (Orth) RCS (Eng), FFDRCSI (Orth.), M Orth RCS (Eng), M Orth RCS (Edin), MFDSRCS (Eng), MFDSRCS (Edin), MFDSRCPs (Glasg), FHEA (UK), FDTFED, Preventive and Restorative Dentistry Department, College of Dental Medicine, Building M28, University of Sharjah, Sharjah, UAE; Director of the Institute of Dentistry, University of Aberdeen, UK, Foresterhill Campus, Cornhill Road, Aberdeen, AB25 2ZR, United Kingdom (e-mail: khalaf@sharjah.ac.ae; ; khaled.khalaf@abdn.ac.uk).

## Abstract

Patients with hypodontia appear to have a different craniofacial morphology as compared with controls. They tend to have more class III skeletal pattern and retroclined upper and lower soft tissue lips as a consequence of retroclined upper and lower incisors. These features are more pronounced as the severity of the hypodontia increases. In addition to changes in craniofacial and soft tissue morphology, various dental anomalies are commonly associated with hypodontia such as microdontia of the remaining dentition, anomalies in tooth shape, particularly peg-shaped upper lateral incisors, smaller root dimensions of some of the permanent teeth, and decreased maxillary and mandibular dental arch widths and lengths measurements. Other dental anomalies which are seen in association with hypodontia are taurodontism of molars, retained deciduous molars, delayed development of the permanent teeth, distoangulation of the mandibular second premolar, and infraocclusion of the deciduous molars.

## Keywords

- ▶ Anomalies
- ▶ Craniofacial
- ▶ Dental
- ▶ Hypodontia
- ▶ Morphology

## Introduction

Hypodontia is defined as the congenital absence of one or more primary or permanent teeth.<sup>1</sup> It is the most prevalent developmental dental anomaly in humans with an overall prevalence of 6.4%. The prevalence varies depending on the population studied, with Africa having the highest prevalence (13.4%) followed by Europe (7%), Asia and Australia (6.3%), and North America (5%) and Latin America (4.4%) having lowest prevalence.<sup>2</sup> The most commonly affected teeth by hypodontia except the third molars are the mandibular second premolars followed by the maxillary lateral incisors, maxillary second premolars, mandibular central incisors, mandibular lateral incisors, maxillary first premolars, mandibular first premolars, maxillary canines, mandibular second molars, maxillary second molars, mandibular canines, maxillary first molars, mandibular first

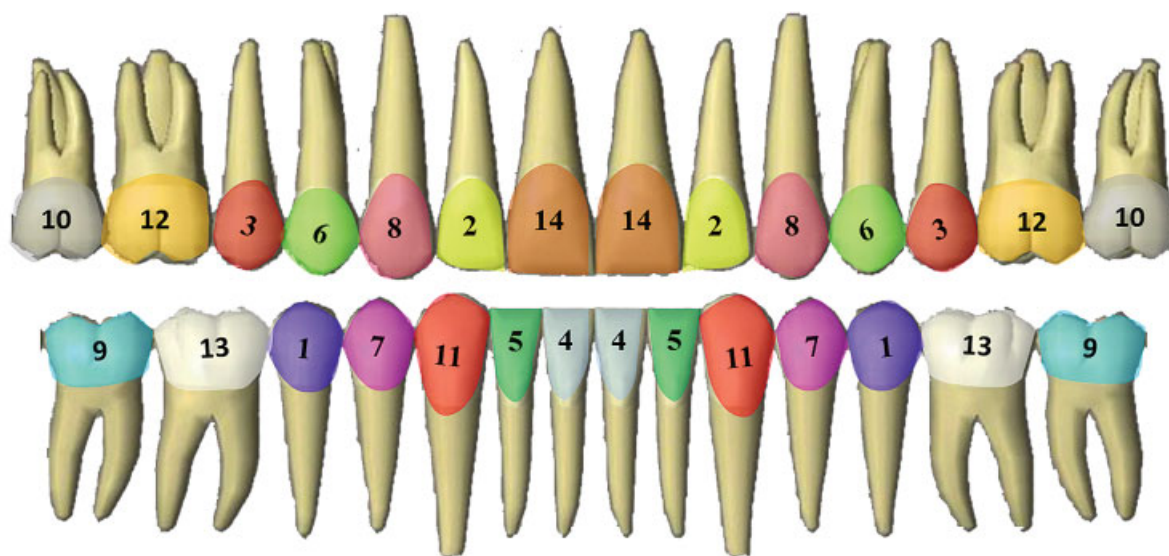
molars and lastly the maxillary central incisors<sup>2</sup> (→**Fig. 1**). In general, this type of dental anomaly is more prevalent in females than males<sup>3</sup> which is contrary to the gender distribution in supernumerary teeth.<sup>4,5</sup> Hypodontia can be classified as either syndromic<sup>6</sup> or non-syndromic or according to the number of congenitally missing teeth into mild with 1 to 2 congenitally missing teeth, moderate with 3 to 5 congenitally missing teeth, and severe with 6 or more congenitally missing teeth.<sup>7</sup> Although the etiological factors of hypodontia are unknown yet, hypodontia is considered to be multifactorial where both genetic and environmental factors have shown to play a role in its etiology.<sup>8</sup> Hypodontia may have a negative impact on the affected individual, such as unaesthetic appearance, speech problems, malocclusion, and periodontal damage.<sup>9</sup> In addition, it can influence the skeletal relationship and reduce the chewing ability.<sup>10</sup>

DOI <https://doi.org/10.1055/s-0042-1742355>.  
ISSN 2320-4753.

© 2022. The Author(s).

This is an open access article published by Thieme under the terms of the Creative Commons Attribution License, permitting unrestricted use, distribution, and reproduction so long as the original work is properly cited. (<https://creativecommons.org/licenses/by/4.0/>)

Thieme Medical and Scientific Publishers Pvt. Ltd., A-12, 2nd Floor, Sector 2, Noida-201301 UP, India



**Fig. 1** A diagram illustrating the frequency of occurrence of congenitally missing teeth from the most affected (1) to the least affected (10) teeth in the permanent dentition.

## Materials and Methods

A comprehensive literature search was undertaken using both PubMed and Google Scholar until March 2021, using the keywords: hypodontia, tooth agenesis, congenitally missing teeth, dental anomalies, and craniofacial morphology. Relevant papers addressing the association between dental anomalies, craniofacial morphology, and hypodontia were then selected and included in this review to provide an insight into the influence of hypodontia on the skeletal structures and to identify the dental anomalies that can occur in association with hypodontia and complicate the management of those patients.

**Exclusion and inclusion criteria:** Only studies addressing hypodontia of the permanent dentition excluding third molars were included in the current review. Studies of hypodontia patients with genetic/medical conditions, such as Down syndrome, ectodermal dysplasia, and cleft lip and palate were also excluded. For articles published in the non-English language, data were taken from the English abstract where possible. No restrictions were applied to the time of publication of articles. Observational, cross-sectional and longitudinal, prospective, and retrospective studies were included. The following publication types were excluded: letters, editorials, post-graduate theses, case reports, and randomized controlled trials.

## Results

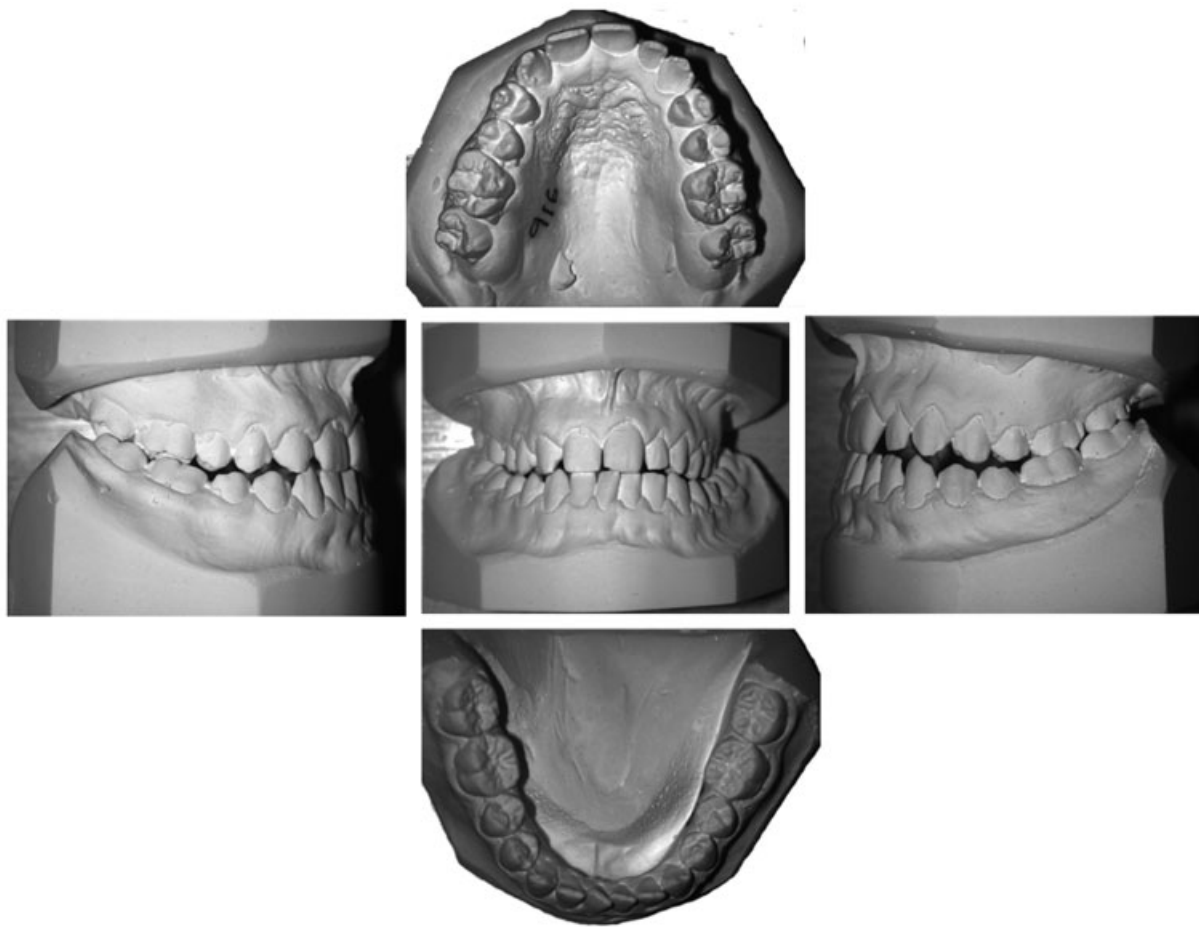
### Skeletal, Incisor Angulations, and Soft Tissue Changes Associated with Hypodontia

It was found by several studies that patients with tooth agenesis had a different craniofacial pattern when compared with patients with a normal number of teeth,<sup>11–16</sup> but few studies have investigated the effect of the distribution of congenitally missing teeth on the craniofacial morphology.<sup>12–17</sup>

According to Endo et al,<sup>17</sup> an anterior and posterior hypodontia exerted a similar pattern on the craniofacial structures. However, skeletal and dental changes were more remarkable in patients having both anterior and posterior congenitally missing teeth. These changes include a greater retroclination of the maxillary incisors, mandibular prognathism, and a greater anticlockwise rotation of the occlusal plane (→ **Figs. 2–4**). Comparing an anterior, posterior, and a combination of both anterior-posterior teeth absence, Ben-Bassat and Brin<sup>12</sup> showed that skeleto-dental pattern was more exacerbated in patients with congenital absence of the anterior teeth. On the contrary, patients with anterior and a combination of anterior-posterior teeth absence showed a similar pattern of skeleto-dental changes.<sup>12</sup>

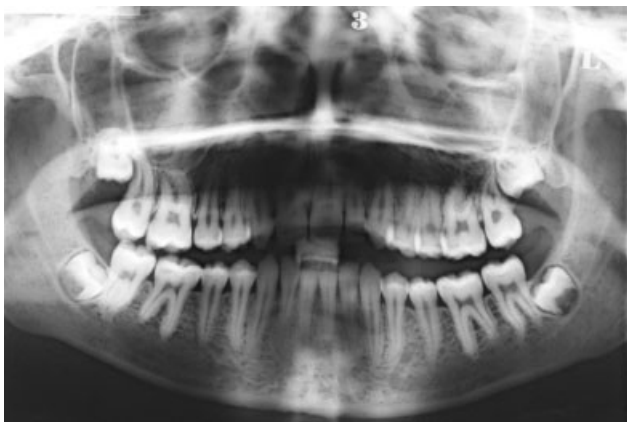It was found that as the severity of hypodontia increased there was more tendency toward developing a skeletal class III malocclusion.<sup>13,16</sup>

According to Ogaard et al,<sup>11</sup> skeletal and soft tissue changes associated with hypodontia are directly related to the severity of the condition, i.e., the number of congenitally missing teeth. Patients with 10 and more congenitally missing teeth had the most notable retroclined pattern of the lower and upper incisors and, therefore, an increase in the interincisal angle. This, in turn, will lead to the loss of support to the upper and lower lips and a decrease in the upper and lower lips prominence and an obtuse nasolabial angle.<sup>11,12,14</sup> In addition, patients with the same number of congenitally missing teeth showed a statistically significant reduction in the SNA (sella, nasion, A point: the deepest point on the anterior border of the maxilla on a lateral cephalometric radiograph) and ANB (A point, nasion, B point: the deepest point on the anterior border of the mandible on a lateral cephalometric radiograph) angles and exhibited a retrognathic maxilla and straight skeletal profile. Furthermore, patients with a severe form of hypodontia showed a reduction in the Frankfort-mandibular plane angle, lower face height, and an increase in the facial

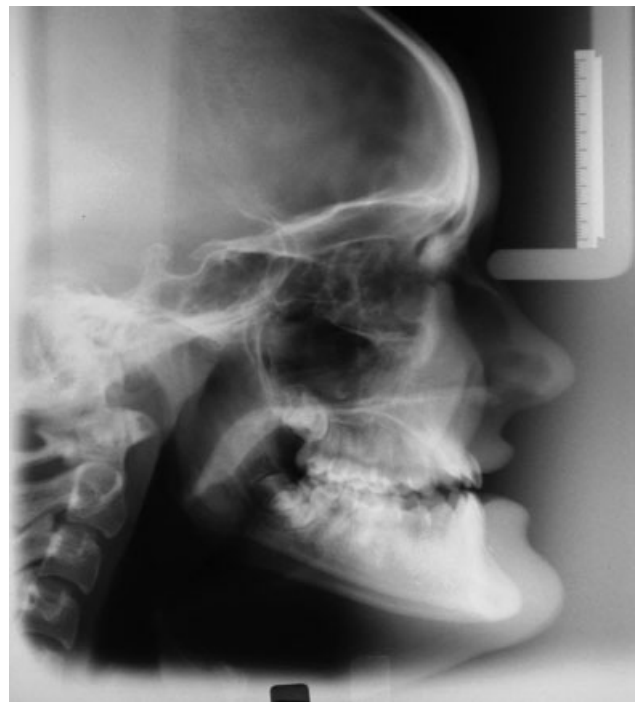

**Fig. 2** Study models of a patient with congenitally missing 12.

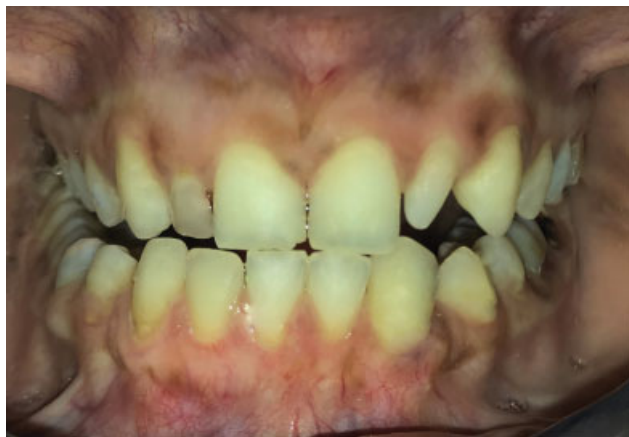axis.<sup>11-13</sup> This decrease in the lower face height can be ascribed to the anterior rotation of the mandible resulting from a smaller number of teeth and, thus, less support.<sup>11,15</sup> Some previous studies have reported a reduction in the length of the maxillary and mandibular alveolar bone in severe hypodontia.<sup>14,16</sup> However, these findings contrast other investigations which showed no reduction in the maxillary and mandibular alveolar bone height in mild or severe forms of hypodontia.<sup>11,18</sup>



**Fig. 3** Orthopantomography of the same patient in Fig. 2 confirming the congenital absence of 12.



**Fig. 4** Lateral cephalometric radiograph of the same patient in Fig. 2 showing a class III skeletal pattern with mandibular prognathism, anticlockwise rotation of the occlusal plane, retroclined lower incisors, and retroclined upper and lower lips.



**Fig. 5** An intraoral photograph of a patient with congenitally missing 32 associated with a peg-shaped 22.

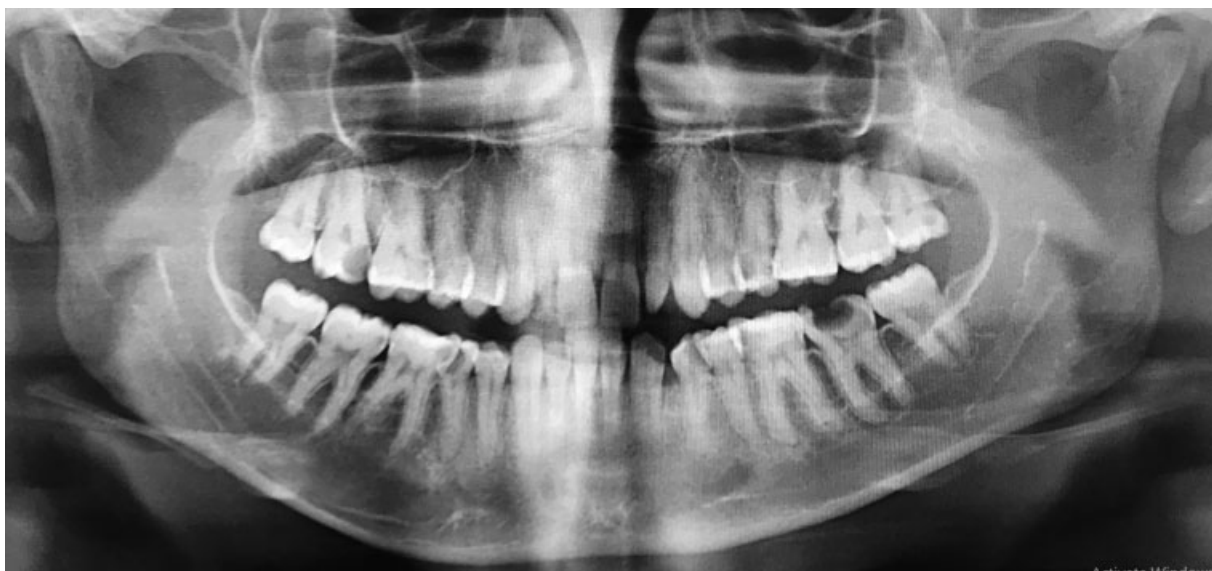### Anomalies of Tooth Size and Shape

A few studies have investigated the relationship between congenitally missing teeth and the mesiodistal and buccolingual dimensions of the clinical crowns of the remaining teeth. A study conducted by Khalaf<sup>19</sup> to investigate tooth crown dimensions in patients with mild, moderate, and severe hypodontia revealed that patients with congenitally missing teeth had significantly smaller teeth in the buccolingual and mesiodistal dimensions than controls. The greatest reduction in tooth measurements was found in patients with severe hypodontia. According to Khalaf's study, the most affected tooth in terms of tooth size reduction was the maxillary lateral incisor and the least affected one was the mandibular first molar. This reduction in tooth crown size was found in both the anterior and posterior segments, thus involving the whole dentition.<sup>19,20</sup> Furthermore, it has been shown that relatives of patients with hypodontia tended to have larger tooth dimensions than their affected relatives, but smaller tooth crown dimensions when compared with a control group.<sup>21,22</sup> These results indicate

that hypodontia and microdontia may form parts of a genetically determined condition<sup>19</sup> and are compatible with the multifactorial theory suggested by Brook to explain the etiology of various dental anomalies in humans.<sup>23</sup> Further support to the multifactorial theory of the etiology of hypodontia has been provided by other studies which showed an association between hypodontia and microdontia.<sup>24,25</sup> A few studies, on the contrary, did not show such an association.<sup>26,27</sup> The disagreement between the findings of the aforementioned studies can be attributed to the racial differences between the population studied, different severities of hypodontia of the included sample, and the use of different methods to measure tooth dimensions. The impact of hypodontia on the remaining dentition is not limited to tooth size but also extends to tooth shape.<sup>28-31</sup> A study conducted by Al-Shahrani et al<sup>28</sup> to compare the shape of the lower left permanent first molar in patients with different severities of hypodontia to a control group showed that the lower left permanent first molar in hypodontia group had a shorter clinical crown, less bulbous labial surface, flatter gingival margin, less prominent buccal cusps tips, flatter occlusal surface, and a decreased taperness of the proximal surfaces toward the occlusal surface when compared with a control.<sup>25</sup> In addition, it was found that patients with hypodontia had a less number of cusps of the upper first permanent molar<sup>29,30</sup> and the lower premolars,<sup>29</sup> an alteration in the shape of the maxillary central incisor including round incisal edge and less tapered proximal surfaces incisally<sup>31</sup> and a peg-shaped maxillary lateral incisor<sup>32</sup> as seen in ►Figs. 5 and 6. Furthermore, it was found that the greater the severity of hypodontia, the more the alteration in the tooth shape.<sup>28</sup>

### Anomalies of Root Length and Width

There is a lack of studies investigating root dimensions in patients with hypodontia. A recent study<sup>33</sup> has compared root length and widths of the permanent teeth in mild hypodontia patients with controls and showed that patients with one or two congenitally missing teeth had a shorter root



**Fig. 6** An orthopantomography of the same patient in (►Fig. 2) with congenitally missing 32 associated with a peg-shaped 22.

length of the upper central incisors, upper canines, first premolars, and lower first molars compared with unaffected controls as well as a decrease in the root width measured at the midpoint of the root length for the upper central incisors, lower first premolars, upper first molars, and all second premolars, and a similar pattern of differences was found with regard to the root width at the cervical region.

### Alteration in Arch Dimensions

A few studies have reported a reduction in arch width and length measurements of patients with congenitally missing teeth compared with a control regardless of the severity of the hypodontia condition.<sup>34,35</sup> However, only one study has compared the mandibular and maxillary arch dimensions including depth, width, and height of the dental arches in patients with mild, moderate, and severe hypodontia with a control group and revealed smaller arch dimensions in all forms of hypodontia. The reduction in arch dimensions in the hypodontia group was directly proportional to the number of congenitally missing teeth with the maxillary arch depth being the most affected measurement in all hypodontia groups.<sup>36</sup> These results are contrary to the findings of other studies which failed to show a reduction in arch dimensions in hypodontia patients. Nevertheless, some of these studies lack unaffected control group<sup>25</sup> and others had a sample of mixed severity with the mild hypodontia being the predominant form.<sup>25,37</sup>

### Other Dental Anomalies Associated with Hypodontia

Other dental anomalies that can occur in association with hypodontia include peg-shaped maxillary lateral incisor, taurodontism of molars, retained deciduous molars, delayed development of the permanent teeth, distoangulation of the mandibular second premolar, and infraocclusion of the deciduous molars.<sup>32,38,39</sup> These anomalies are also observed in relatives of first and second generations of hypodontia-affected patients.<sup>39</sup> Other less common anomalies which can be associated with hypodontia are supernumerary teeth, transmigration, transposition, and ectopic eruption of the permanent molars.<sup>32,38</sup>

### Clinical Implications

- Patients with hypodontia tend to have a class III skeletal pattern. Therefore, it is important for clinicians when they see hypodontia patients in the mixed dentition stage especially with moderate or severe condition to bear in mind that those patients are likely to grow unfavorably presenting a more severe class III as the mandibular growth ceases. This will have a significant bearing on the treatment plan in the short and long terms.
- Patients with hypodontia also present with a variety of dental anomalies especially those with moderate and severe hypodontia. Having a sound and accurate knowledge of these anomalies will help the multidisciplinary team members involved in the management of hypodontia patients to choose the most appropriate treatment

plan, organizing and coordinating each aspect of the treatment plan, planning/selecting the most appropriate anchorage during the orthodontic phase of the treatment plan delivery, planning the type and timing of the restorative and prosthodontic phases of treatment, and subsequently optimizing treatment outcome by achieving upper and lower dental arch alignments, good overjet, overbite, eliminating any center line discrepancies and good buccal segments interdigitation.

### Conclusions

Patients with hypodontia appear to have a different craniofacial morphology as compared with controls. They tend to have more class III skeletal pattern and retroclined upper and lower soft tissue lips as a consequence of retroclined upper and lower incisors. In addition to changes in craniofacial and soft tissue morphology, and various dental anomalies are commonly associated with hypodontia such as microdontia of the remaining dentition, anomalies in tooth shape, particularly peg-shaped upper lateral incisors, smaller root dimensions of some of the permanent teeth, and decreased maxillary and mandibular dental arch widths and lengths measurements. Craniofacial morphology changes and dental anomalies in hypodontia patients are more pronounced as the severity of the condition increases.

### Funding

This research did not receive any specific grant from funding agencies in the public, commercial, or not-for-profit sectors.

### Conflict of Interest

None declared.

### References

- 1 Roslan AA, Rahman NA, Alam MK. Dental anomalies and their treatment modalities/planning in orthodontic patients. *J Orthod Sci* 2018;7:16–16
- 2 Khalaf K, Miskelly J, Voge E, Macfarlane TV. Prevalence of hypodontia and associated factors: a systematic review and meta-analysis. *J Orthod* 2014;41(04):299–316
- 3 Mattheeuws N, Dermaut L, Martens G. Has hypodontia increased in Caucasians during the 20th century? A meta-analysis. *Eur J Orthod* 2004;26(01):99–103
- 4 Brinkmann JC, Martínez-Rodríguez N, Martín-Ares M, et al. Epidemiological features and clinical repercussions of supernumerary teeth in a multicenter study: a review of 518 patients with hyperdontia in Spanish population. *Eur J Dent* 2020;14(03):415–422
- 5 Alhashimi N, Al Jawad FHA, Al Sheeb M, Al Emadi B, Al-Abdulla J, Al Yafei H. The prevalence and distribution of nonsyndromic hyperdontia in a group of Qatari orthodontic and pediatric patients. *Eur J Dent* 2016;10(03):392–396
- 6 Chen AY-C, Chen K. Dental treatment considerations for a pediatric patient with incontinentia pigmenti (Bloch-Sulzberger syndrome). *Eur J Dent* 2017;11(02):264–267
- 7 Brook AH, Elcock C, al-Sharood MH, McKeown HF, Khalaf K, Smith RN. Further studies of a model for the etiology of anomalies of tooth number and size in humans. *Connect Tissue Res* 2002;43(2-3):289–295

- 8 Yamaguchi T, Tomoyasu Y, Nakadate T, Oguchi K, Maki K. Allergy as a possible predisposing factor for hypodontia. *Eur J Orthod* 2008;30(06):641–644
- 9 Goya HA, Tanaka S, Maeda T, Akimoto Y. An orthopantomographic study of hypodontia in permanent teeth of Japanese pediatric patients. *J Oral Sci* 2008;50(02):143–150
- 10 Khosravanifard B, Ghanbari-Azarnir S, Rakhshan H, Sajjadi SH, Ehsan AM, Rakhshan V. Association between orthodontic treatment need and masticatory performance. *Orthodontics (Chic)* 2012;13(01):e20–e28
- 11 Ogaard B, Krogstad O. Craniofacial structure and soft tissue profile in patients with severe hypodontia. *Am J Orthod Dentofacial Orthop* 1995;108(05):472–477
- 12 Ben-Bassat Y, Brin I. Skeletodontal patterns in patients with multiple congenitally missing teeth. *Am J Orthod Dentofacial Orthop* 2003;124(05):521–525
- 13 Takahashi Y, Higashihori N, Yasuda Y, Takada JI, Moriyama K. Examination of craniofacial morphology in Japanese patients with congenitally missing teeth: a cross-sectional study. *Prog Orthod* 2018;19(01):38
- 14 Bondarets N, McDonald F. Analysis of the vertical facial form in patients with severe hypodontia. *Am J Phys Anthropol* 2000;111(02):177–184
- 15 Taju W, Sherriff M, Bister D, Shah S. Association between severity of hypodontia and cephalometric skeletal patterns: a retrospective study. *Eur J Orthod* 2018;40(02):200–205
- 16 Bajraktarova Miševska C, Kanurkova L, Bajraktarova Valjakova E, et al. Craniofacial morphology in individuals with increasing severity of hypodontia. *South Eur J Orthod Dentofac Res* 2016;3(01):11–16
- 17 Endo T, Ozoe R, Yoshino S, Shimooka S. Hypodontia patterns and variations in craniofacial morphology in Japanese orthodontic patients. *Angle Orthod* 2006;76(06):996–1003
- 18 Khalaf K. Alveolar bone height in patients with mild hypodontia. *J Int Dent Med Res* 2016;9(01):64–69
- 19 Khalaf K. Tooth size in patients with mild, moderate and severe hypodontia and a control group. *Open Dent J* 2016;10:382–389
- 20 Brook AH, Elcock C, Aggarwal M, et al. Tooth dimensions in hypodontia with a known PAX9 mutation. *Arch Oral Biol* 2009;54(Suppl 1):S57–S62
- 21 McKeown HF, Robinson DL, Elcock C, al-Sharood M, Brook AH. Tooth dimensions in hypodontia patients, their unaffected relatives and a control group measured by a new image analysis system. *Eur J Orthod* 2002;24(02):131–141
- 22 Schalk-van der Weide Y, Bosman F. Tooth size in relatives of individuals with oligodontia. *Arch Oral Biol* 1996;41(05):469–472
- 23 Brook AH. A unifying aetiological explanation for anomalies of human tooth number and size. *Arch Oral Biol* 1984;29(05):373–378
- 24 Baccetti T. A controlled study of associated dental anomalies. *Angle Orthod* 1998;68(03):267–274
- 25 Woodworth DA, Sinclair PM, Alexander RG. Bilateral congenital absence of maxillary lateral incisors: a craniofacial and dental cast analysis. *Am J Orthod* 1985;87(04):280–293
- 26 Küchler EC, Risso PA, Costa MdeC, Modesto A, Vieira AR. Studies of dental anomalies in a large group of school children. *Arch Oral Biol* 2008;53(10):941–946
- 27 Chung CJ, Han JH, Kim KH. The pattern and prevalence of hypodontia in Koreans. *Oral Dis* 2008;14(07):620–625
- 28 Al-Shahrani I, Dirks W, Jepson N, Khalaf K III. 3D-Geomorphometrics tooth shape analysis in hypodontia. *Front Physiol* 2014;5:154
- 29 Kerekes-Máthé B, Brook AH, Mártha K, Székely M, Smith RN. Mild hypodontia is associated with smaller tooth dimensions and cusp numbers than in controls. *Arch Oral Biol* 2015;60(09):1442–1449
- 30 Kondo S, Townsend GC. Associations between Carabelli trait and cusp areas in human permanent maxillary first molars. *Am J Phys Anthropol* 2006;129(02):196–203
- 31 Robinson DL, Blackwell PG, Stillman EC, Brook AH. Planar Procrustes analysis of tooth shape. *Arch Oral Biol* 2001;46(03):191–199
- 32 Choi SJ, Lee JW, Song JH. Dental anomaly patterns associated with tooth agenesis. *Acta Odontol Scand* 2017;75(03):161–165
- 33 Khalaf K, Seraj Z, Hussein H, Mando M. Root dimensions in patients with mild hypodontia and a control group. *Eur J Dent* 2019;13(04):574–580
- 34 Fekonja A. Comparison of mesiodistal crown dimension and arch width in subjects with and without hypodontia. *J Esthet Restor Dent* 2013;25(03):203–210
- 35 Willmot DR, Nelson T, Elcock C, Smith RN, Robinson DL, Brook A. The use of computerised image analysis to measure the form and dimensions of the maxillary dental arches in subjects with hypodontia. In: Brook A, ed. *Dental Morphology*. United Kingdom: Sheffield Academic Press Ltd; 2001:239–246
- 36 Khalaf K. Dental arch dimensions in patients with mild, moderate and severe hypodontia and a control group. *Int J Innov Res Med Sci* 2016;1(09):338–344
- 37 Wisth PJ, Thunold K, Bøe OE. Frequency of hypodontia in relation to tooth size and dental arch width. *Acta Odontol Scand* 1974;32(03):201–206
- 38 Al-Abdallah M, AlHadidi A, Hammad M, Al-Ahmad H, Saleh R. Prevalence and distribution of dental anomalies: a comparison between maxillary and mandibular tooth agenesis. *Am J Orthod Dentofacial Orthop* 2015;148(05):793–798
- 39 Arte S, Nieminen P, Apajalahti S, Haavikko K, Thesleff I, Pirinen S. Characteristics of incisor-premolar hypodontia in families. *J Dent Res* 2001;80(05):1445–1450